



# JOE DE BEER & ASSOCIATE

ORTHOPAEDIC SHOULDER SURGEON • ORTOPEDIESE SKOUER CHIRURG

J F de Beer, K van Rooyen, D Bhatia

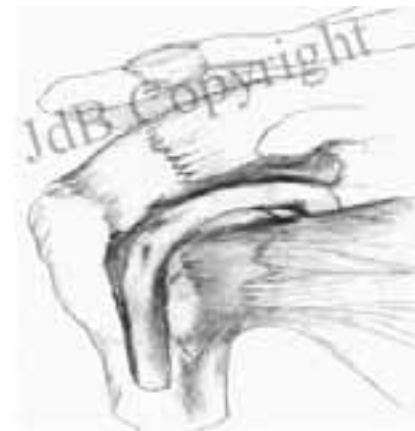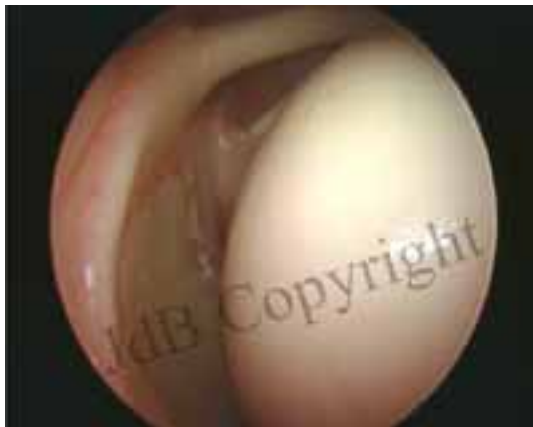## The Biceps tendon

### Anatomy:

The Biceps is an *upper arm muscle* that acts across the shoulder and elbow joints. At the elbow, it helps to bend the joint. At the shoulder, its function is more complex and incompletely understood.

The biceps has *two tendons* around the shoulder: the *long tendon* passes inside the joint via a groove in the ball and attaches to the upper end of the shoulder socket, and the *short tendon* passes outside the joint to an adjacent bony outgrowth (coracoid).

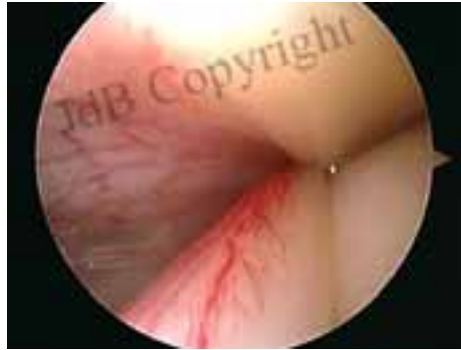*The long tendon of the biceps is the problematic entity in shoulder pain.*



Arthroscopic view (left) and diagrammatic representation (right) of the Biceps tendon passing through the groove.

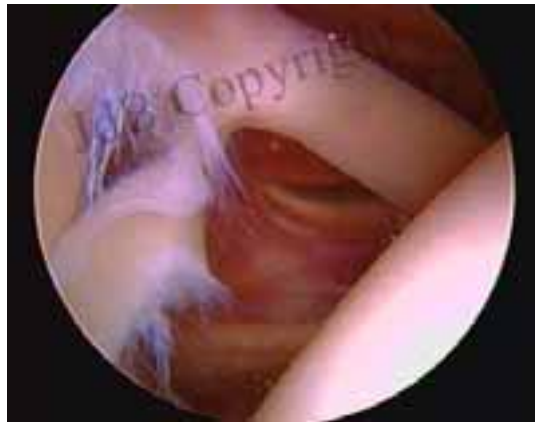## Diseases/disorders of the tendon:

1. Inflammation of the tendon: Bicipital tendonitis. The Long tendon of the biceps slides in a groove on the shoulder ball during movements of the arm. Friction between the surfaces result in “soreness” of the tendon, called “Tendonitis”. Within the shoulder, the tendon appears “Red” with tiny blood vessels on its surface. Untreated, the tendonitis progresses to fraying and tears.



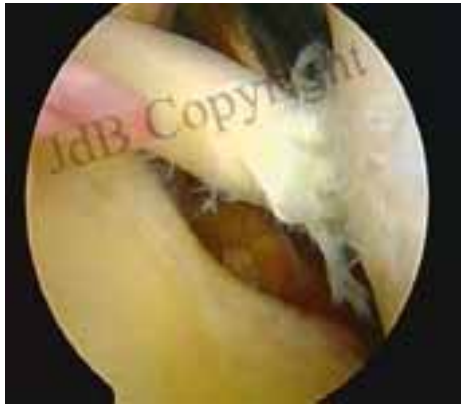Bicipital tendonitis.

2. Fraying/ partial tearing of the tendon. Persistence of friction on an inflamed tendon leads to this condition. The tendon appears frayed, which implies separation of individual fibres.



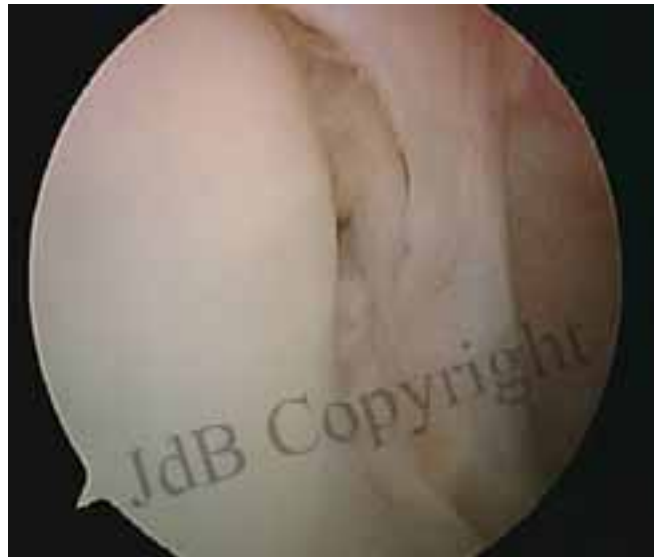Frayed/torn biceps tendon.

3. Complete tears/ Rupture of the tendon. Persistence of friction on a frayed out tendon leads to this condition. The tendon cannot be seen from within the joint as it slips into the groove on the ball. The resultant slack on the muscle leads to a “Popeye” like muscle deformity.



Torn biceps tendon.

4. Tears around the tendon attachment at the upper end of the shoulder socket (SLAP tears). These are seen in throwing athletes.



SLAP tear: separation of biceps tendon attachment from the upper end of the shoulder socket.

## **Diagnosis:**

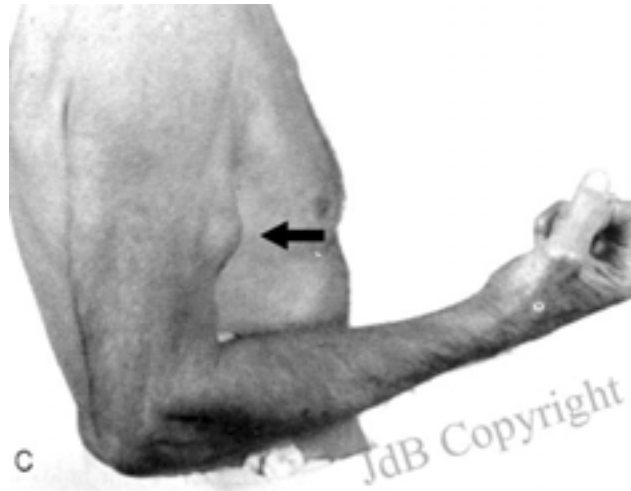
### **CLINICAL:**

Biceps tendon disorders can present in different ways.

1. Pain: Pain around the front of the shoulder, arm and sometime passing down the upper limb is suggestive. The pain occurs with movements of the arm (mechanical in nature)

Pressure on the groove is painful, and an injection of a local anaesthetic drug in the groove, under ultrasound control, provides relief.

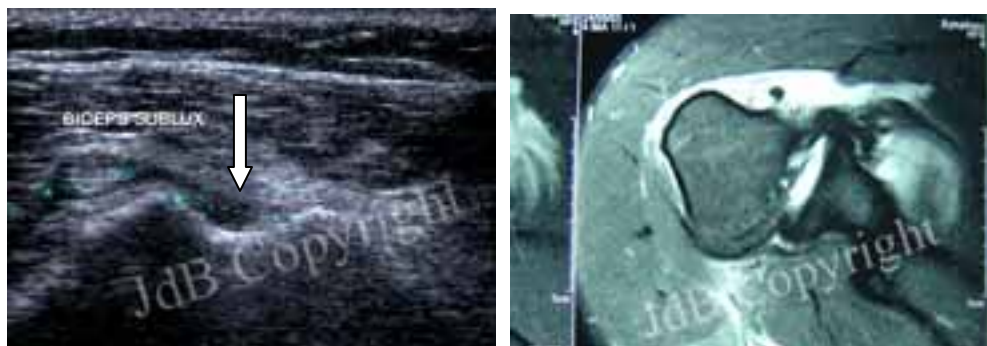2. Clicking: Partially torn tendon and SLAP tears can cause obstruction to movements of the arm and gives an unpleasant sensation of “clicking”.
3. Deformity: Complete tears of the biceps tendon can result in a “Popeye” like muscle appearance.



## **RADIOLOGICAL:**

Xrays do not reveal biceps problems.

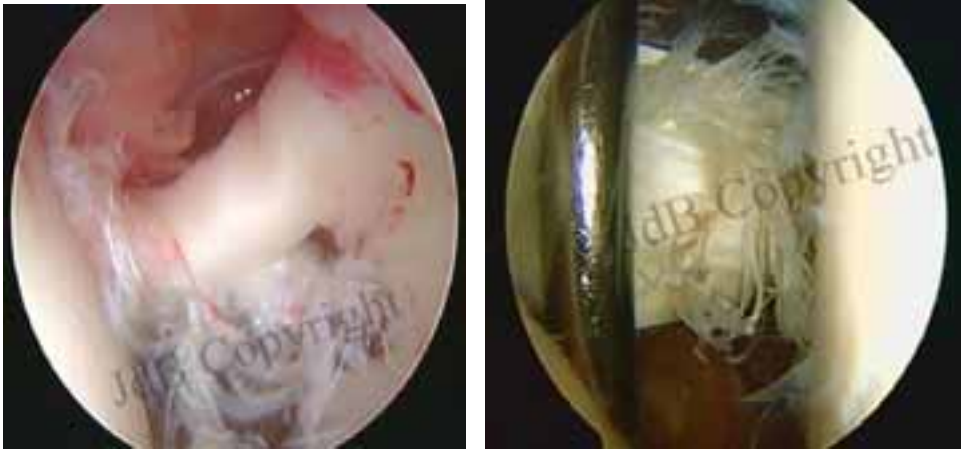
MRI and ultrasound are sometimes useful. Fluid around the tendon, and displacement out of the groove are some of the indicators of possible biceps pathology.



Arrows show an empty groove on ultrasound (left) and MRI (right).

## **ARTHROSCOPY:**

Arthroscopy accurately shows the inflamed, frayed, or torn biceps tendon, and SLAP tears.

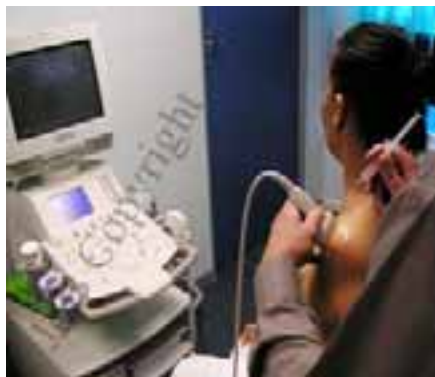

Arthroscopy shows a damaged biceps tendon (left and right).

## **Treatment:**

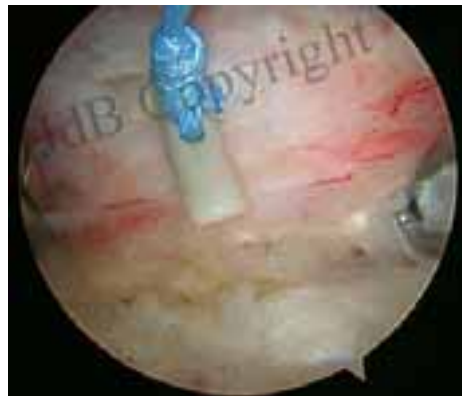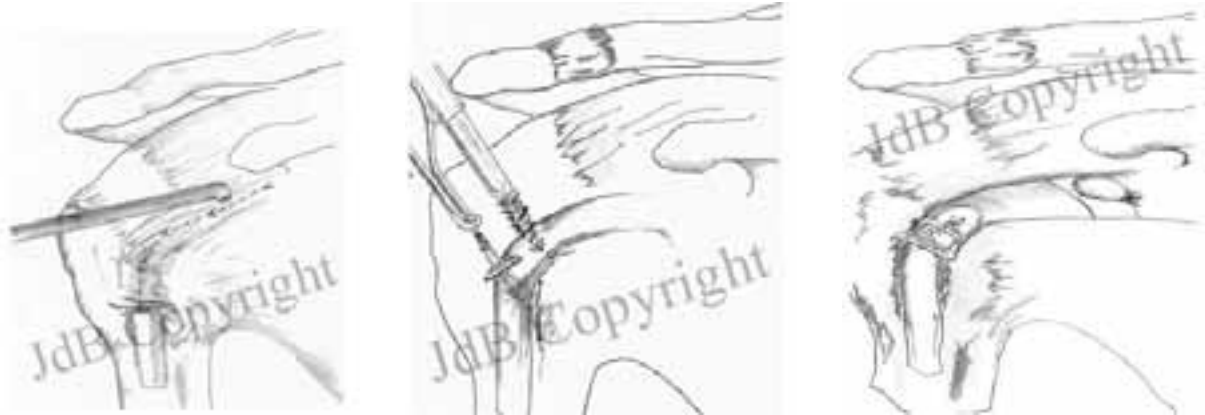### **Conservative:**

1. Avoidance of movements that cause shoulder pain.
2. Cortisone injections into the groove, under ultrasound control, to reduce inflammation.



## Surgical:

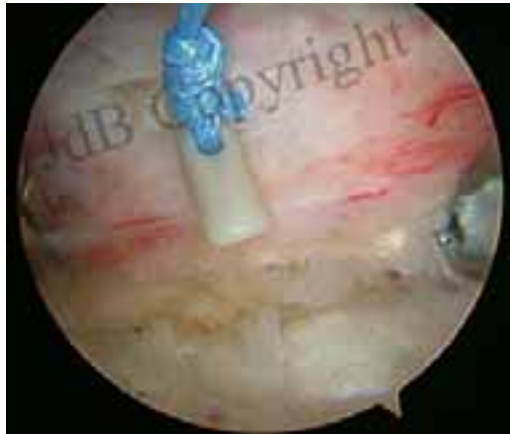Arthroscopy identifies the problem and should be used to simultaneously treat the problem. The biceps tendon is detached from its attachment on the upper socket and is transferred to a hole created in the groove on the ball using biodegradable screws or anchors (*Biceps tenodesis*). This eliminates the sliding of the tendon and thereby removes friction. Pain relief is immediate and complete.



Transfer of the tendon to the groove using metal/biological screws and devices.

Another method that can be used in elderly individuals is simply detaching the tendon from the socket and allowing it to slip down the groove (*Biceps tenotomy*). Although similar to a rupture, this method has been shown to provide excellent relief of pain and is ideal in patients for whom a cosmetic deformity is not an issue.

SLAP tears are repaired arthroscopically to the detached area of bone using tiny anchors. Severe tears are excised and the tendon may be transferred to the groove as described above.



**Post-operative care:**

Post-operative care: The arm should be rested till the repair is firmly in place. Usually, three weeks of rest is sufficient. Thereafter, gradual passive and active exercises are begun and continued till full function is achieved.