



JOE DE BEER & ASSOCIATE

ORTHOPAEDIC SHOULDER SURGEON • ORTOPEDIESE SKOUEER CHIRURG

J F de Beer, K van Rooyen, D Bhatia

OSTEOARTHRITIS OF THE SHOULDER

INTRODUCTION

The shoulder joint (gleno-humeral joint) is one of the most mobile joints in the body. The gleno-humeral joint consists of a ball (humeral head) and socket (glenoid). As in any other joint, the bone surfaces are covered with a specialised cartilage layer.

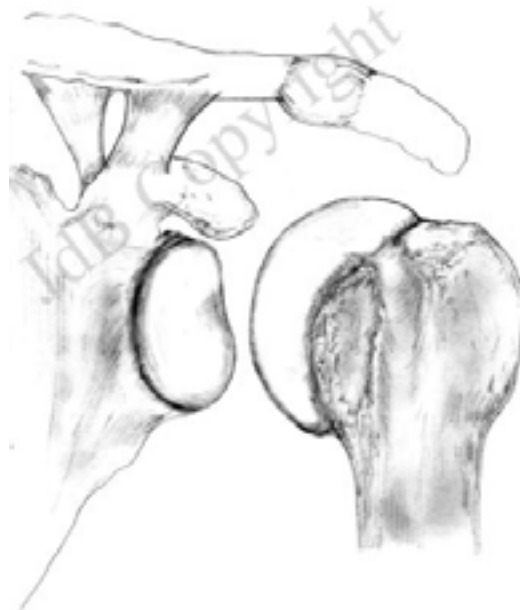

Fig. 1 Normal joint with smooth, intact cartilage surfaces both on the humeral head (ball) and the glenoid (socket)

When this cartilage layer wears away, it results in bone on bone contact. Cartilage is a specialised tissue which contains no nerve supply – this is the reason why our joints can move painlessly. On the other hand bone has a very dense nerve supply and this why an osteo-arthritic joint becomes painful – due to the fact that the cartilage has now disappeared and there is now bone contacting rough bone.

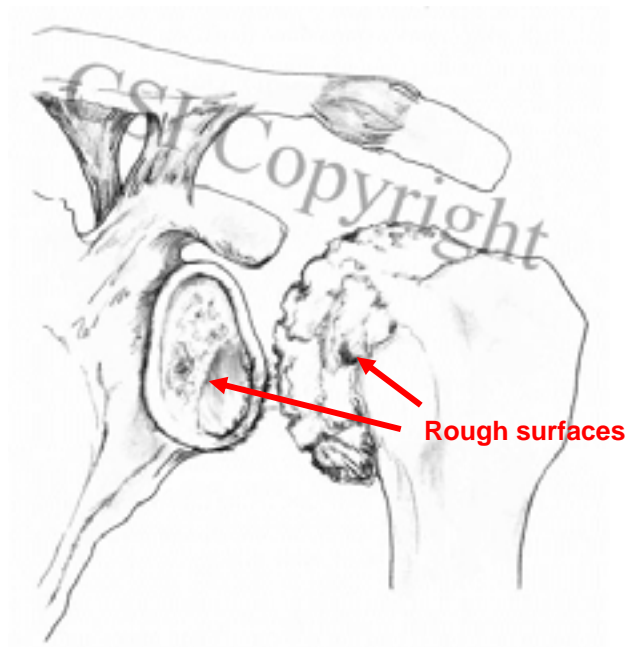


Fig 2.The joint surfaces where cartilage has worn away with rough bare bone contacting bone

The causes of osteo-arthritis are usually not known -it may result from previous trauma but this is only in rare cases. Other specific joint diseases like rheumatoid arthritis usually lead to severe destruction of most joints in the body.

SYMPTOMS AND SIGNS

The osteo-arthritic joint becomes painful with limited range of motion and night pain can be an important feature. A “grating” feeling may be experienced in the joint and this may even be audible. A feeling of catching or slipping may also be felt due to the rough surfaces moving over each other

DIAGNOSIS

The diagnosis is made by clinical examination by the physician as well as x-rays.

On examination the doctor may find decreased range of motion and some very painful movements. The grating may even be audible!

On x-ray a narrow joint space with osteophytes (bony ridges on the side of the articulating surface) are noted (Fig. 3). In some cases of early osteoarthritis x-rays may not reveal the diagnosis, especially if only a circumscribed area of cartilage is lost on the humeral head (Fig 4).

CT scan is often recommended to look at the joint in a 3-dimensional perspective to evaluate the wear of especially the glenoid (socket) which is common in osteo-arthritis of the shoulder joint. The wear is often more at the back of the joint than at the front.

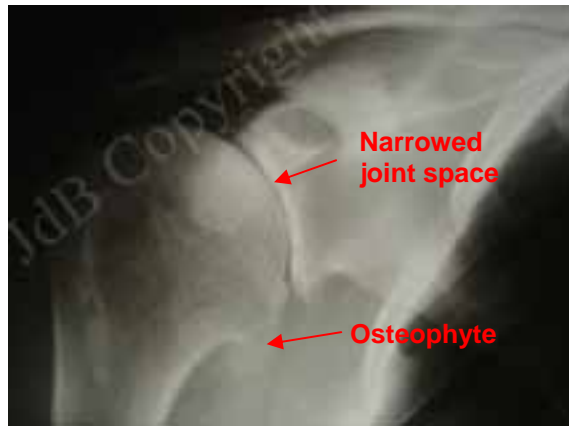


Fig 3: X-ray of an osteoarthritic shoulder joint- the narrowed joint space and osteophyte can be seen

MRI is less important to evaluate an arthritic joint except if the doctor wants to evaluate the status of the tendons of the shoulder

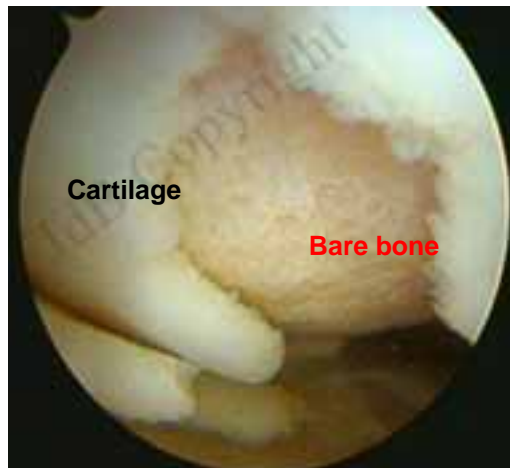


Fig. 4: Localised area of cartilage loss on the head of the humerus

MANAGEMENT OF OSTEOARTHRITIS

1. In the early management anti-inflammatory tablets and pain tablets can be efficient.
2. Physiotherapy – pain relieving modalities using physiotherapy may be of value in the early phases.

3. Cortisone injections – cortisone injections may have a marked relieving effect but they have to be placed inside the gleno-humeral joint and not into the subacromial space (the latter is where most cortisone injections into the shoulder are administered). In our unit we do this injection under ultra-sound control to ensure that it is accurately placed into the joint

4. Arthroscopy – arthroscopic “lavage” or “wash out” is an operation where an arthroscope is placed into the joint and “cleaning out” of the joint is done. This is a small procedure with few complications and will serve to confirm the diagnosis and often has a pain relieving effect. It is never curative. During such an arthroscopic procedure small areas of loss of cartilage on the surface of the humeral head may be seen (localised osteo-chondral defects) and can be treated surgically by doing “micro-fracture”. This is when small holes are drilled on the surface of the defect and could promote ingrowth of fibro-cartilage which is a scar type of tissue and can serve as a barrier against bone to bone contact (Fig. 5)

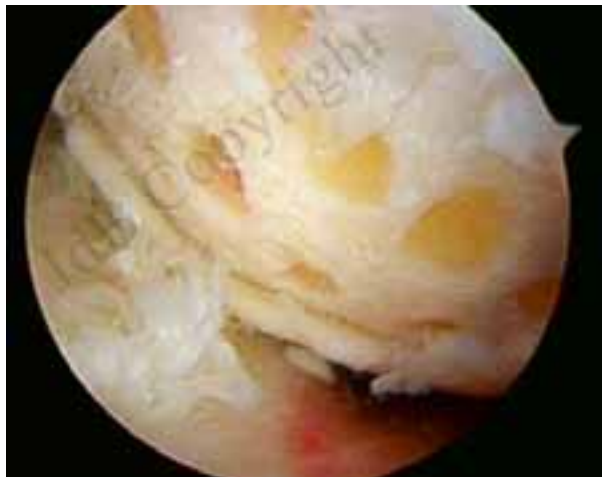

Fig 5: small holes are drilled arthroscopically into the area of localized cartilage loss – also referred to as “micro-fracturing” The aim is to stimulate the ingrowth of cartilage-like tissue to cover the defect

i5. Soft tissue interposition – in this procedure a soft tissue membrane is implanted on the socket. The purpose is to have fibrous tissue (scar tissue) grow into this membrane and act as a barrier against bone to bone contact. Various such membranes have been tried and various ones are available.

INTERPOSITION GRAFT FOR OSTEOARTHRITIS OF THE SHOULDER (OUR METHOD)

We developed an arthroscopic method of resurfacing the osteo-arthritic shoulder joint. The product preferred by ourselves is the "Graft Jacket®". This is human skin derived from donors and is provided commercially. It has been de-cellularised and sterilised, in other words all cells have been removed from the tissue and only the fibrous lattice remains which will act as a scaffold for cell ingrowth. The surface of the glenoid (socket) is roughened up with special instruments and the Graft Jacket membrane is sutured onto the surface using arthroscopic methods. Stem cells will provide ingrowth of cartilage-like tissue into the membrane and form a structure resembling cartilage.

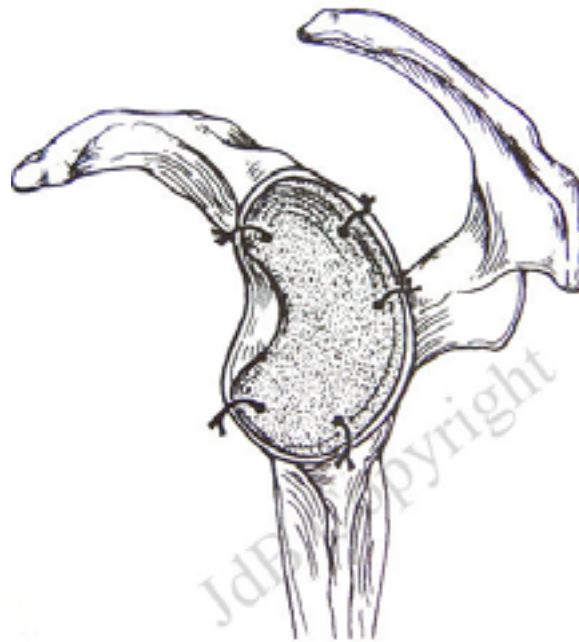


Fig 6: This picture shows the principle of soft tissue interposition- a membrane is fixed to the surface of the glenoid and will act as a scaffold for the ingrowth of cartilage-like material to act as a barrier between the bare bone surfaces of the joint

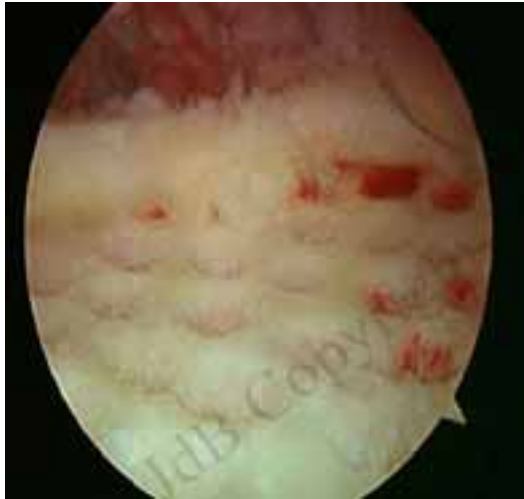

Fig 7: The first step of the arthroscopic soft tissue interposition procedure. Small holes are made on the surface of the glenoid and this will stimulate cells to grow into the covering membrane which will change into cartilage-like tissue. This is the view seen with the arthroscope

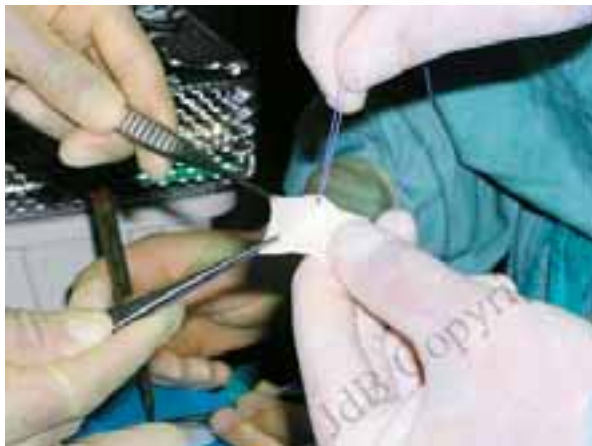

Fig. 7: The graft ("Graft Jacket") is being prepared outside the body

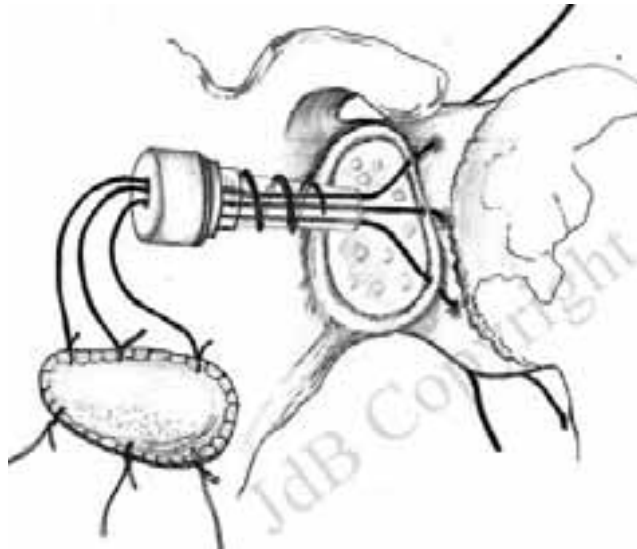


Fig 8: Drawing shows how the graft is being passed into the shoulder through an arthroscopic cannula

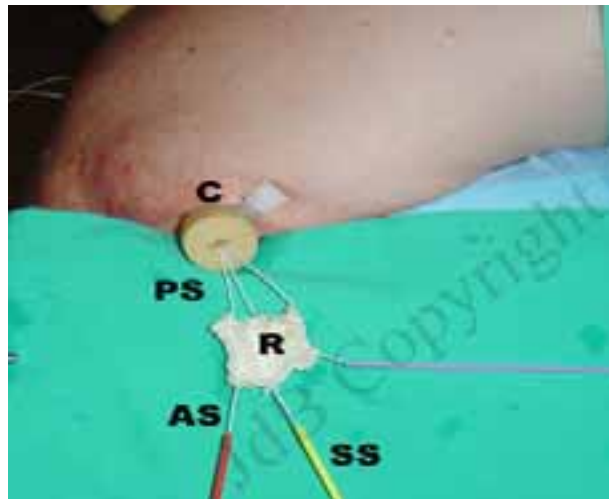


Fig 9: The operation viewed from the outside- it is being performed under arthroscopic (key-hole) control. The "Graft Jacket" (R) has been attached to sutures (AS,SS and PS) and is passed through an arthroscopic cannula (C) The sutures are being used to draw the Graft Jacket into the joint and will also be used to fix the graft to the tissues inside the joint

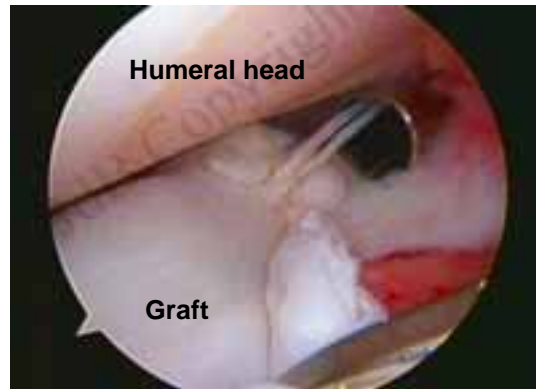


Fig 10: Inside view of the joint: The sutures are being used to fix the graft to the surface of the glenoid. During the first few weeks after the operation the patient has to keep the arm still to allow the graft to grow on to the surface of the glenoid while the sutures hold it in position.

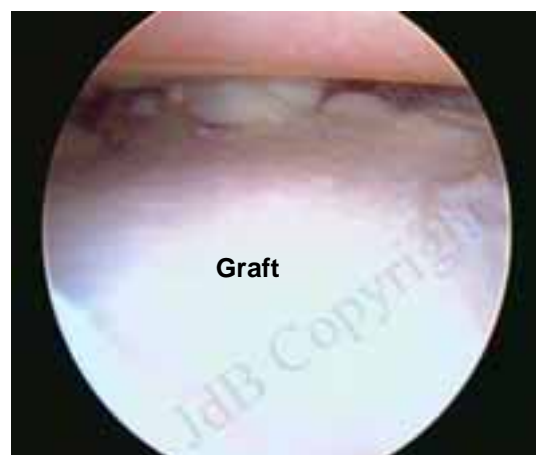

Fig 11: At the end of the procedure the graft can be seen to lie flat on the surface of the glenoid, being held in position by sutures- it resembles a carpet having been laid on a floor.

Post operatively the patient's arm is put in a sling for 3 weeks and little movement is allowed to enable the membrane to fix itself to the surface of the socket.

After the operation:

The patient is usually kept in the hospital overnight and discharged the next morning. The arm is immobilised in a sling for 3 weeks for the membrane to grow on to the surface of the bone. After this gradual mobilisation is allowed. The benefit of the procedure will only be apparent after 4-6 months due to the fact that the tissue has to grow into the graft, with the graft acting as a lattice or scaffold. Once the pain-free state has been reached most activities are allowed.

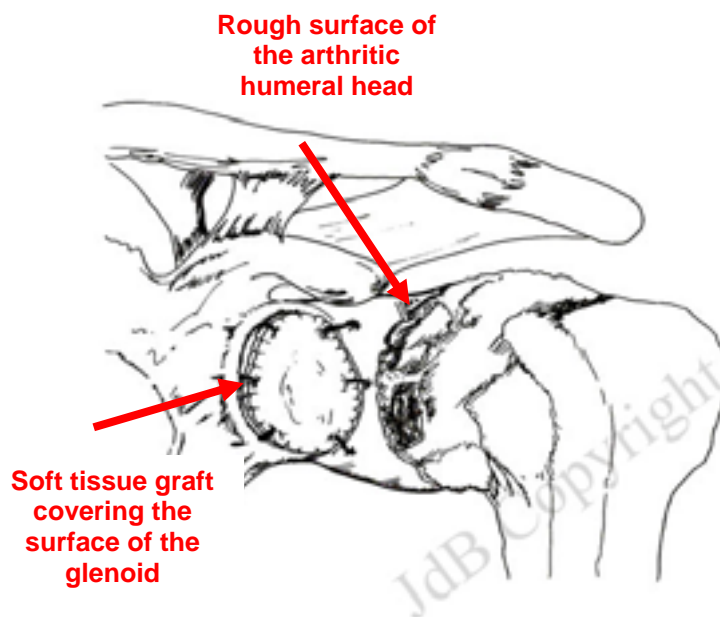


Fig. 12. The “Graft Jacket” has been attached to the glenoid (socket). It would act as a “scaffold” for “cartilage-like tissue to grow into the membrane. The tissue acts a barrier between the rough, arthritic surfaces.

RESULTS

So far our results have been most encouraging: over the past 4 years 56 patients have been operated. In more than 70% the results have been excellent. Taking into account that the alternative would be joint replacement (metal and polyethylene prosthesis) the results are therefore most satisfactory when one weighs up the minimal intervention compared to open joint replacement. We favour this method for younger patients where a prosthesis would not be indicated. This is also preferred for patients not accepting the limitation of activities imposed on them after a formal joint replacement

JOINT REPLACEMENT (ARTHROPLASTY)

In this procedure there are various options, ranging from small metal covers for the humeral head ("Hemi Cap"), larger covers also referred to as "resurfacing prostheses" (e.g. the Copeland resurfacing prosthesis) and total prostheses where the humeral head is removed and a metal head is cemented into the humeral shaft.

1. Resurfacing of the humeral head with the "HemiCap" prosthesis. The HemiCap is a relatively small metal disc which is screwed into the head and the disc part of the prosthesis then covers the area of bare bone on the head of the humerus. The advantage is that only the affected area is covered. This prosthesis is not cemented and is probably the next best after soft tissue interposition and certainly an excellent option if the soft tissue interposition is not indicated. The results are generally excellent. Should revision be necessary at a later stage it would be a relatively easy procedure.

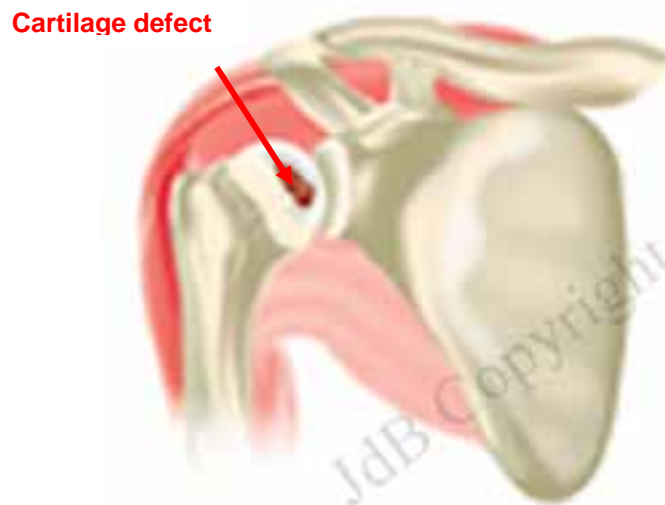


Fig. 13. Area of localized cartilage loss on the humeral head. It can probably be regarded as a small area of arthritis on the head

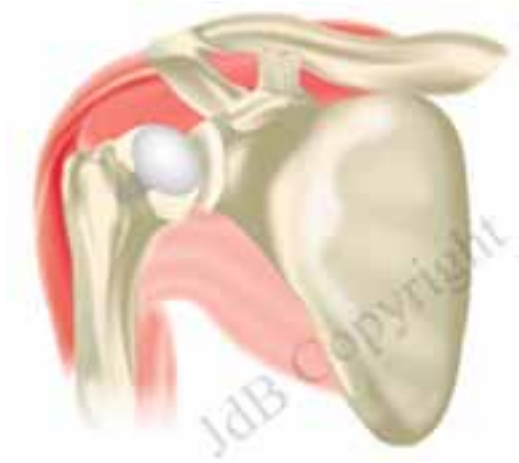

Fig. 14. The metal disc (Hemi-Cap) has been screwed into the head of the humerus, covering the defect

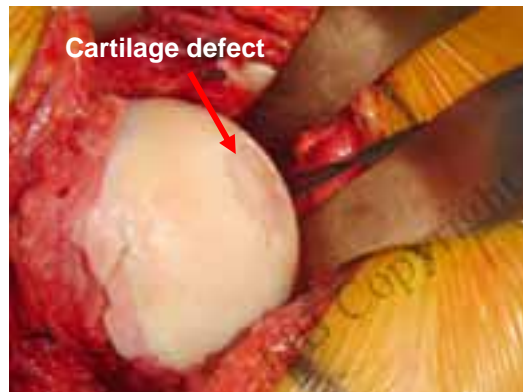


Fig.15. The head of the humerus of a patient during an operation-the cartilage defect seen on the humeral head.

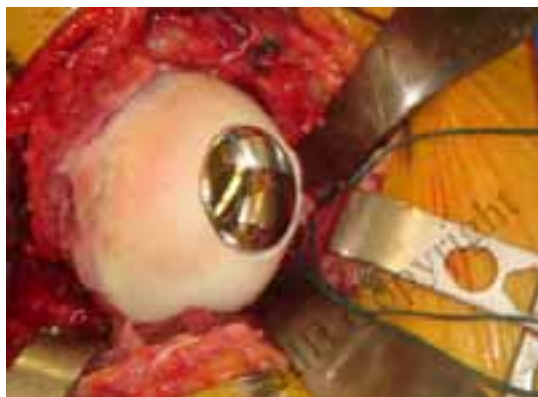

Fig.16. The Hemi-Cap screwed into the head and the disc covering the defect

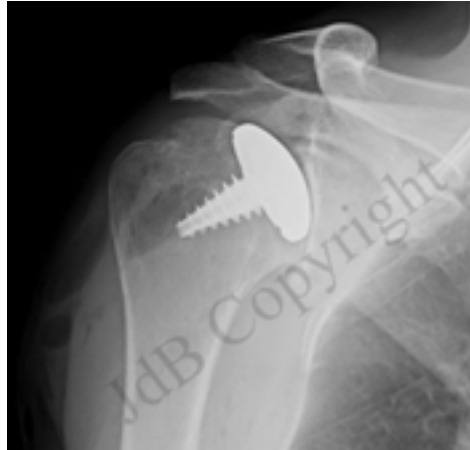


Fig.17. X-ray appearance of a Hemi-Cap having been fixed into the humeral head (ball of the joint)

2. Resurfacing metal prosthesis

A metal prosthesis (larger than the HemiCap) is placed onto the humeral head and acts as a barrier to avoid bone to bone contact. As for the HemiCap it would be indicated for younger patients where later revision procedures may be needed- as this type of prosthesis makes further surgery fairly easy for the surgeon.

2 Cemented hemi-prosthesis

A metal prosthesis is cemented into the humeral shaft to replace the osteo-arthritic head of the humerus. This is favoured for:

- a) certain fractures where the humeral head has a damaged blood supply.
- b) avascular necrosis – where a part of the humeral head has undergone bone death due to a problem with its blood supply
- c) osteoarthritis in younger patients where the procedures mentioned above are not indicated and where the surgeon still avoids a total shoulder replacement due to the problems that a glenoid insertion may lead to (mostly loosening of the glenoid prosthesis).

3 Total shoulder replacement

the humeral head as well as the glenoid socket is replaced with a metal prosthesis and polyethylene (plastic) glenoid prosthesis. This is mostly favoured for older patients with osteoarthritis and the results are most satisfactory in this group. In the older population group there is less activity, less muscular strength and thus less force on the prosthesis with the prosthesis then lasting much longer than in younger, more active individuals. The total prosthesis has been used for many years and is an excellent option for those older individuals

The shoulder replacement operation:

A CT scan is usually requested before the operation to evaluate the adequacy of the bone for the glenoid part of the replacement..

We usually admit the patient to the hospital the evening before the operation and this will allow the anaesthetist to evaluate the patient.

At the end of the operation the arm will be immobilised in a shoulder sling for a day or two simply for pain relief. On awakening from the anaesthetic there will be no pain as the anaesthetist would have placed a nerve block to keep the shoulder and arm numb and pain-free for a few hours. Early motion in the hospital will be encouraged.

After a day or two the patient will be allowed to be discharged, mostly not needing a sling. He or she will be encouraged to start using the arm for everyday activities of daily living- a very gentle and natural form of easy rehabilitation.

Pain and discomfort usually subsides gradually and increasing activity is allowed within pain limits. Clerical type of duties are usually possible after about 4 weeks and full recovery after 2-3 months.

It is our opinion that a total prosthesis is not done for a patient to return to strenuous activities like heavy lifting, contact sports, etc. Most gentle activities are permitted like gardening, playing golf, and similar. For the person with aspirations of more intense activities the less invasive procedures, as mentioned above, are more suitable.(soft tissue interposition and the resurfacing procedures)

An important reason for choosing the less invasive procedures in the younger and higher risk patients is the implication should the prosthesis fail. See below:

What problems could be experienced with prostheses?

a) A prosthesis could become infected. Infection in any prosthesis is a serious problem and the infection is usually very difficult to cure, often requiring the removal of the prosthesis. This is not a common complication

b) A prosthesis may dislocate. The reasons may be

- rupture of one of the rotator cuff muscles, especially the subscapularis muscle
- the shoulder had a tendency to dislocate before the prosthesis was inserted
- the prosthesis was not placed in the correct version (angle) by the surgeon

-there might be muscle paralysis e.g. the deltoid muscle

c) The prosthesis may loosen or wear out- this usually happens in time and is more relevant with increased activity

The solution for the above complications is usually to remove the prosthesis and replace it with a new one ("revision"). It is easily understood that to remove a cemented prosthesis from the humeral shaft is risky and difficult and may result in a fracture of the bone. On the other hand, to remove and revise the less invasive prostheses (e.g. the Hemi-Cap), is relatively easy with fewer complications

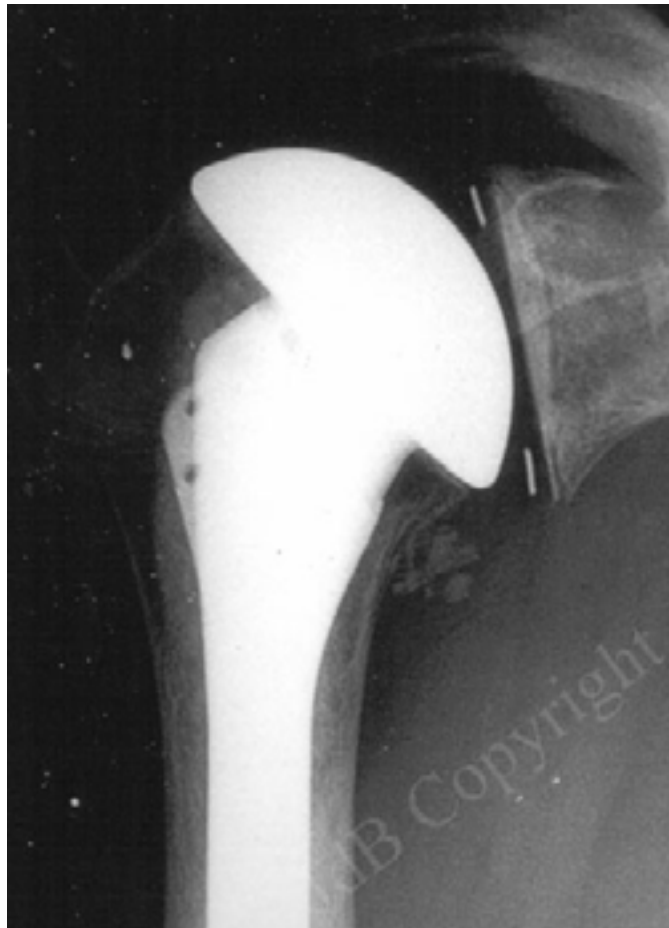

Fig18: A total shoulder prosthesis. The humeral component is cemented into the shaft of the humerus and the glenoid component is cemented into the bone of the glenoid.

This type of prosthesis usually gives excellent pain relief and good function, but the concern is how long it would last. It is usually recommended to be reserved for older, less active patients, who usually do very well with this type of prosthesis and it may last their whole remaining life span. The main problem with this type of prosthesis is that should it fail it is very difficult revise (replace with a new one)



Fig.19. The metal prosthesis which is cemented into the humerus. The ball on top replaces the head of the humerus (which is arthritic) and the stem of the prosthesis is cemented into the the shaft for fixation of the prosthesis

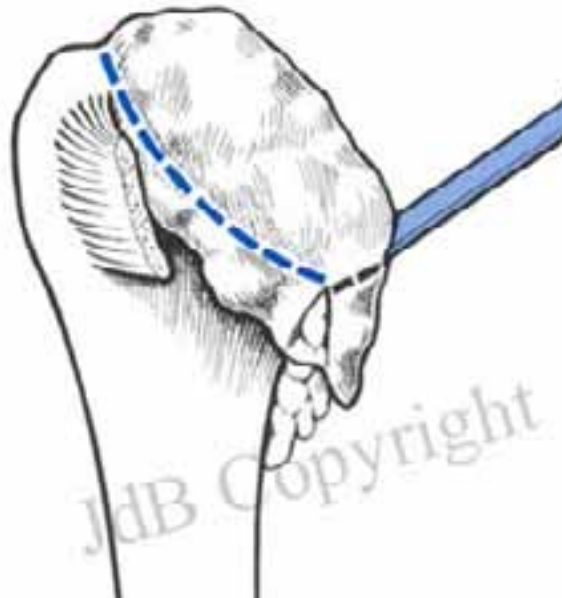


Fig.20. The first step of the shoulder replacement is to remove the arthritic, deformed head of the shoulder.

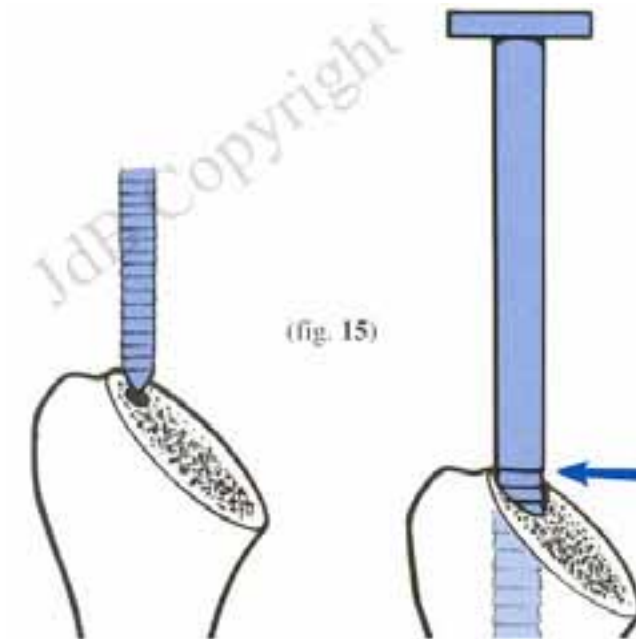


Fig.21. The shaft of the humerus is then prepared to receive the prosthesis which will be cemented into the hollow shaft

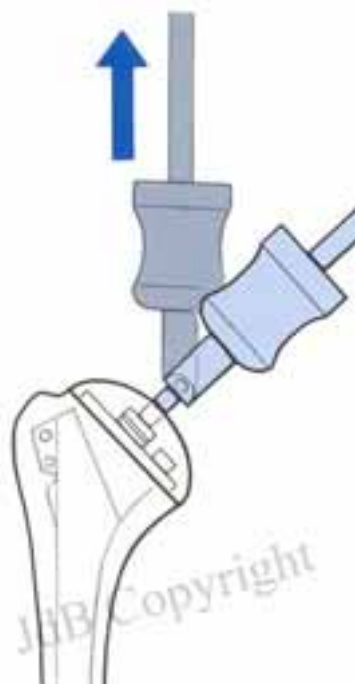

Fig.22. The prosthesis is then placed down the shaft and is fixed with cement to the inside of the shaft. There are certain types of prostheses which are uncemented and rely

Following the humeral aspect of the procedure the glenoid (socket) is then prepared for the glenoid part of the prosthesis. A slot or holes are made into the socket and a plastic (polyethylene) prosthesis is then cemented into the glenoid

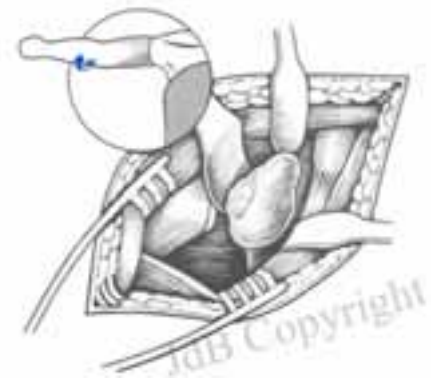

Fig.23. Inserting the glenoid prosthesis into the glenoid (socket) is the second part of the procedure. In this drawing the exposure for preparation of the glenoid is demonstrated



Fig.24. The polyethylene (plastic) prosthesis
Which is cemented into the glenoid.

Reverse prosthesis

- this type of prosthesis is specifically designed for arthritis where the rotator cuff muscles have disappeared due to chronic degenerative tears and the tendons are not repairable. The prosthesis is specifically designed for older people and acts as a “hinge” enabling the deltoid muscle to lift the arm again, without needing the rotator cuff muscles to elevate the arm.

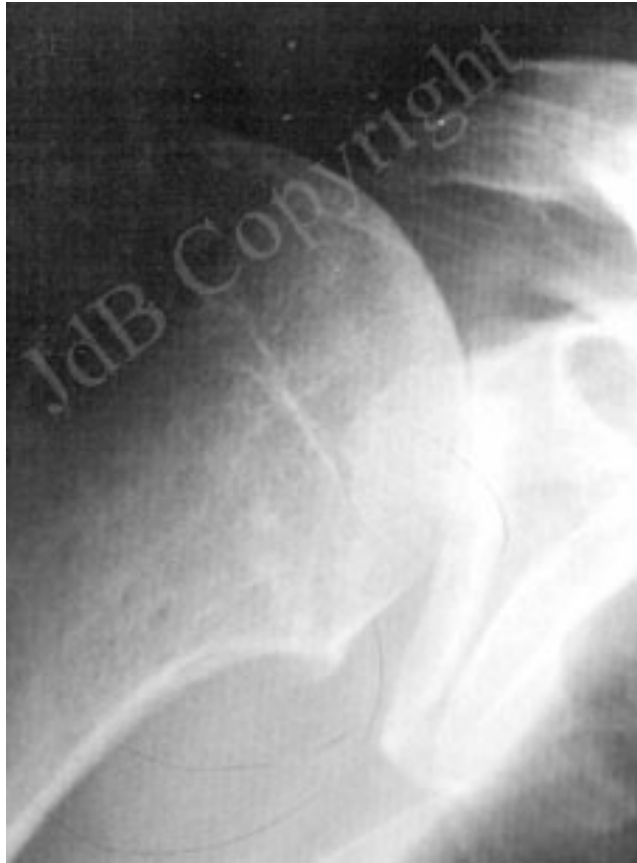

Fig 25: Arthritis of the shoulder with absent rotator cuff. The ball (humeral head) has moved up and out of the socket(glenoid). Due to this disturbed anatomy a normal joint replacement is not indicated as it would loosen and will not improve function. Neither does it provide satisfactory pain relief in most cases

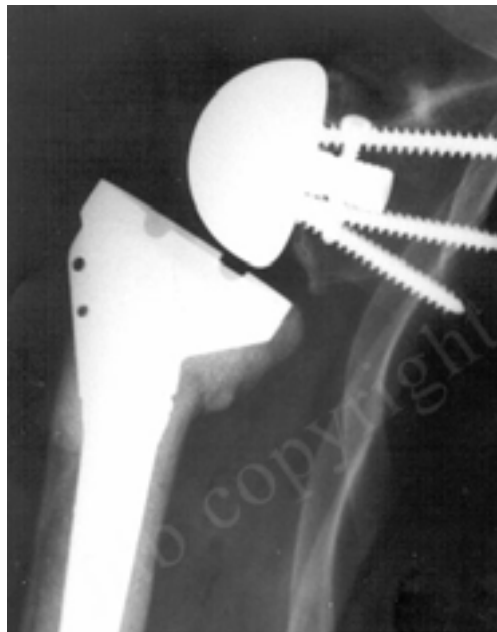

Fig 26: The “hinge” design of the “Reverse” Prosthesis enables the deltoid muscle to elevate the arm and prevents the joint from dislocating

This prosthesis usually enables the patient to elevate the arm again after not being able before the operation. The life span of this type of prosthesis is regarded as shorter than the other prostheses mentioned above and is recommended for older people only.