



JOE DE BEER & ASSOCIATE

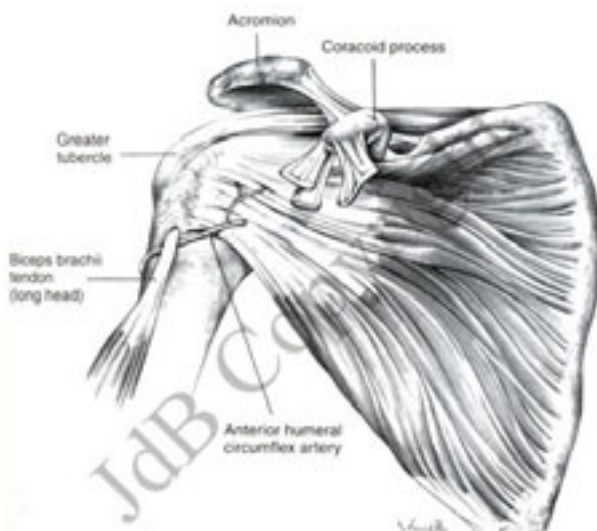
ORTHOPAEDIC SHOULDER SURGEON • ORTOPEDIJSE SKOUER CHIRURG

Joe de Beer, Karin vanRooyen, Deepak N Bhatia.

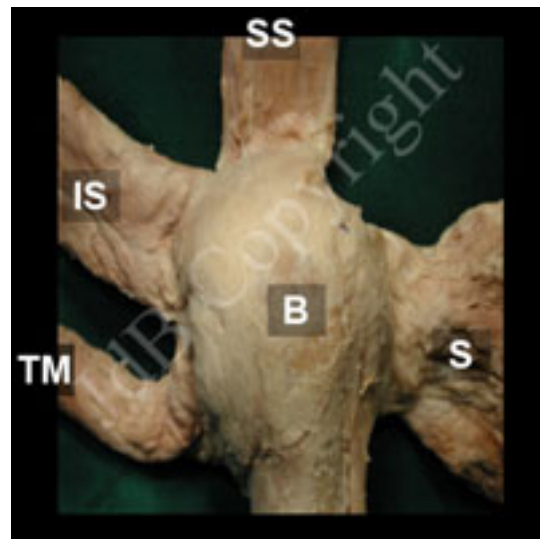SUBSCAPULARIS TENDON TEARS

Introduction

The subscapularis is a most important muscle at the anterior (front) of the shoulder joint. It is often mentioned separately from the rest of the rotator cuff (supraspinatus, infraspinatus and teres minor) but is essentially part of this group of muscles running from back to front covering the head of the humerus (ball of the shoulder joint)



Subscapularis muscle and its attachments



Subscapularis muscle in relation to other muscles. S=Subscapularis, SS=supraspinatus, IS=infraspinatus,

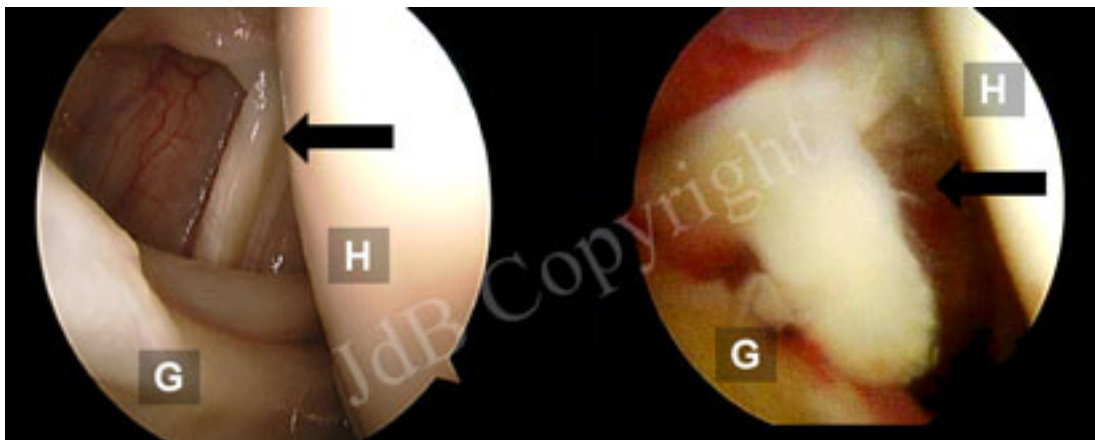The action of the subscapularis is to internally rotate the shoulder joint and act as a main stabiliser of the head in the socket.

Tears of the subscapularis

These are often due to injuries eg. the ***patient falls with an outstretched arm or the arm is forced backwards through some force.***

Characteristically these injuries are ***very painful immediately after the tear and the following few weeks.*** Apart from being painful there will always also ***be weakness when trying to lift the arm or reach underneath the armpit on the other side.***

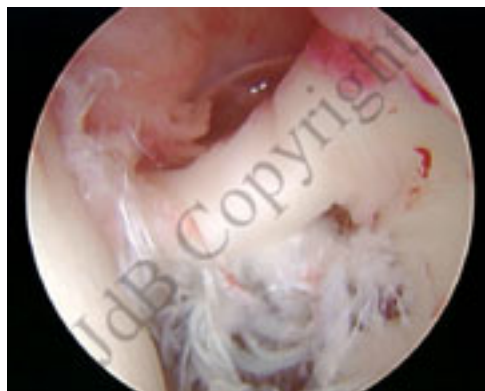Some tears can also be due to degeneration (“wear and tear”). Note that tears of the subscapularis may be isolated or in combination with the rest of the rotator cuff tendons often with supraspinatus.



Arthroscopic view of the subscapularis tendon. Left: Normal, Right: Torn subscapularis.

H=humeral head (ball), G=glenoid (socket).

In many instances the subscapularis tear may be associated with a biceps tendon which has slipped out of its groove and literally cut through the subscapularis tendon.



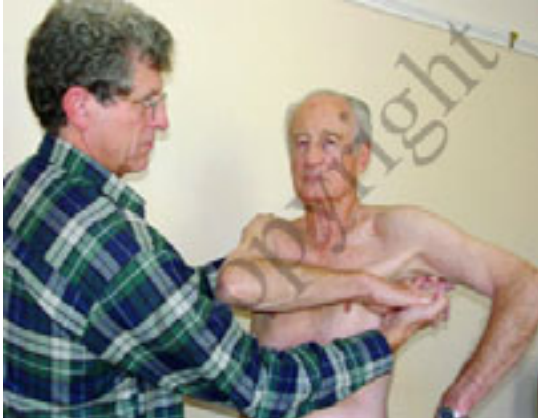Frayed and dislocated biceps tendon.

Diagnosis:

1. Clinical:

DeBeer's hug test:

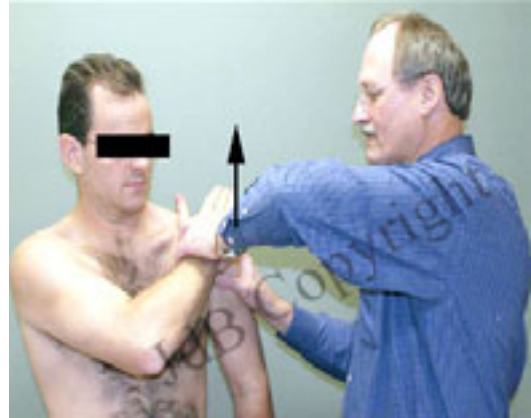Bear-hug test (Burkhart and de Beer)



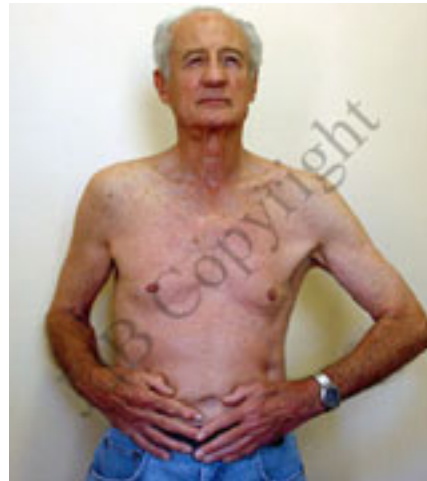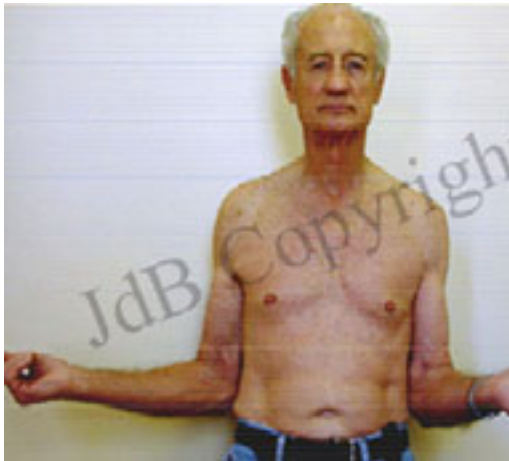
Increased outward movement of the Belly-

press test.

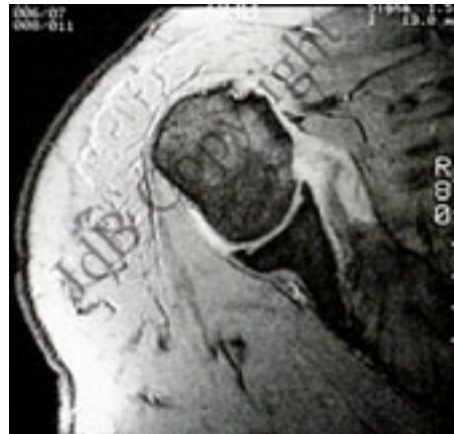Arm (passive external rotation)



2. Radiological diagnosis:

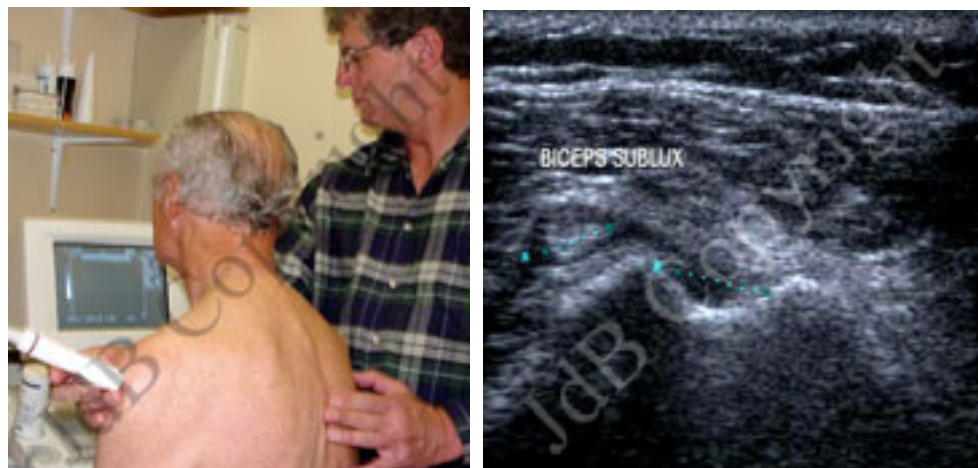

MRI



MRI shows tears and fatty changes in muscle.

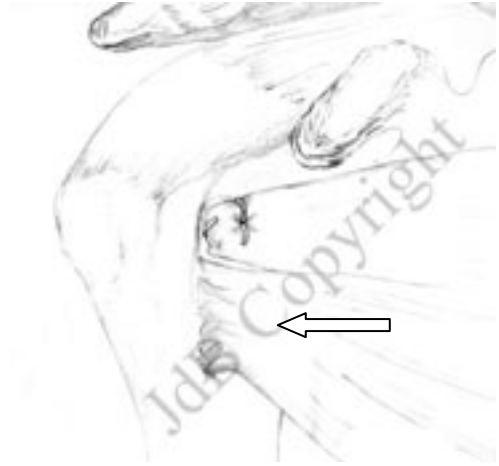
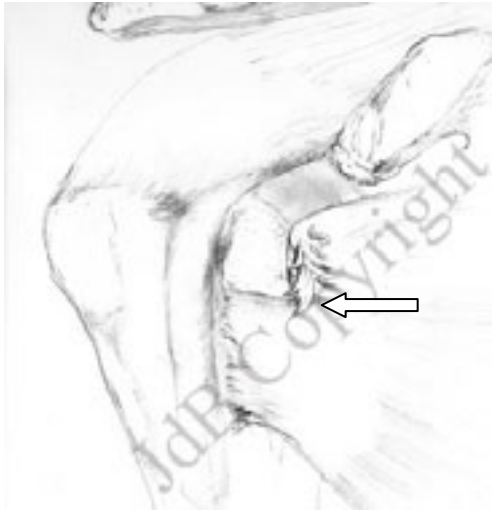Ultrasound:



Ultrasound accurately shows subscapularis tears and biceps tendon involvement.

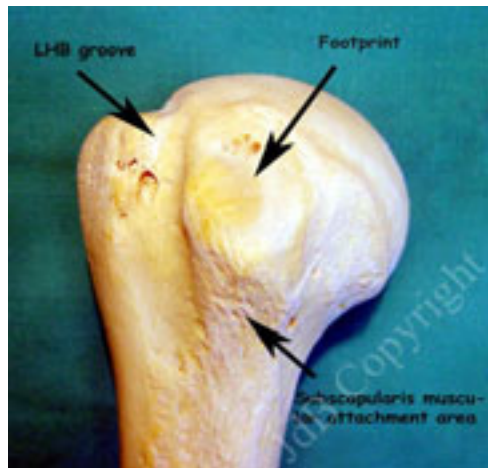
Management of this injury

It is generally accepted that there is little room to leave these tears unrepaired. Progressively the shoulder function may become worse and the tear become irreparable. (repair of these tears is usually done arthroscopically by ourselves but open repair may also be done if the surgeon so prefers)



Left: tear of the subscapularis tendon (arrow).

Right: area of attachment of the subscapularis tendon.



Area of attachment of subscapularis tendon.

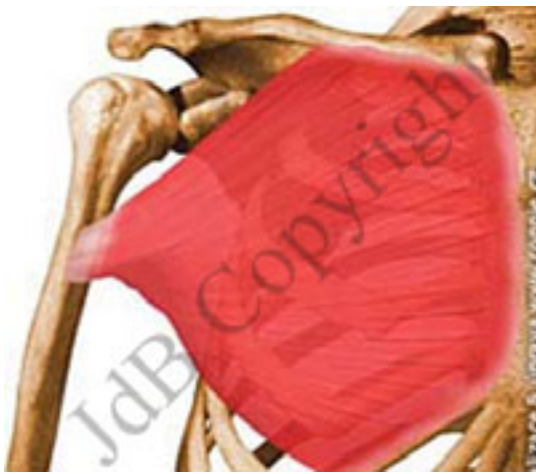Following the repair the arm will be immobilised in a shoulder sling with the arm internally rotated hanging in a comfortable position across the body and active motion will be allowed as time progresses between 4-6 weeks.

Irreparable subscapularis tears:

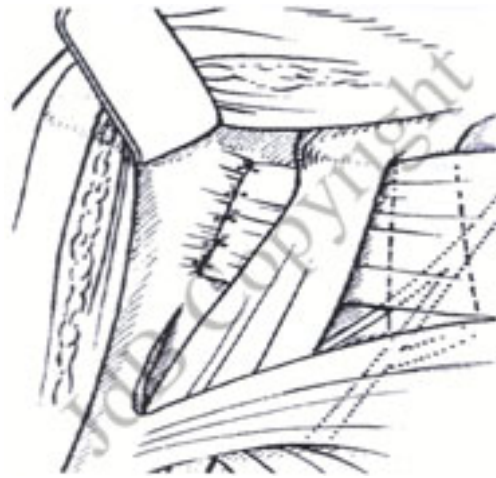
Sometimes, it is impossible to repair old and “withered” tendons. In these cases, a tendon transfer may be performed to “balance” the shoulder joint.

The tendon to be transferred is the Pectoralis major (Pecs) muscle.

The pec major muscle is aligned in the same direction as the subscapularis, and often replicates its function, fully, or partly.



Left: Pectoralis major muscle.



Right: Tendon transfer.